



The Canine Fitness Centre Ltd.
4515 Manhattan Rd SE
Calgary, Alberta T2G 4B3
Phone: (403) 204-0823 Fax: (403) 204-0609
www.caninefitness.com

June 15, 2018

Made Up Owner
1234 Somewhere Dr.
Calgary, AB T1T 1T1

Report on Doggy McDog
DOB: December 15, 2008
Spayed Female Boxer

Thank you for scheduling a Sporting Dog Assessment on **June 7, 2018!** We are pleased to provide you with the following report of Doggy McDog's findings.

Reported Current Activity Level

Daily walks for approximately 25 minutes at a brisk pace; many rounds of fetch in the backyard; training for various dog sports (rally, obedience, agility, tracking)

Other Medical Conditions

None

Veterinarian

Dr. Vetty McVetterson,

Measurements:

Proximal Thigh Circumference: Right Hind, 42.5cm; Left Hind, 41cm

Distal Thigh Circumference: Right Hind, 33cm; Left Hind, 34 cm

Forearm circumference: Right Fore, 16cm; Left Fore, 17cm

Upper arm circumference: Right Fore, 22cm; Left Fore, 21cm

Comments: These are fairly symmetric measurements from side to side. No concerns are noted here.


Chest circumference: 77.5cm

Waist circumference: 60cm


Height: 59.5cm

Weight: 33.5kg / 74lbs


Infrared Thermography



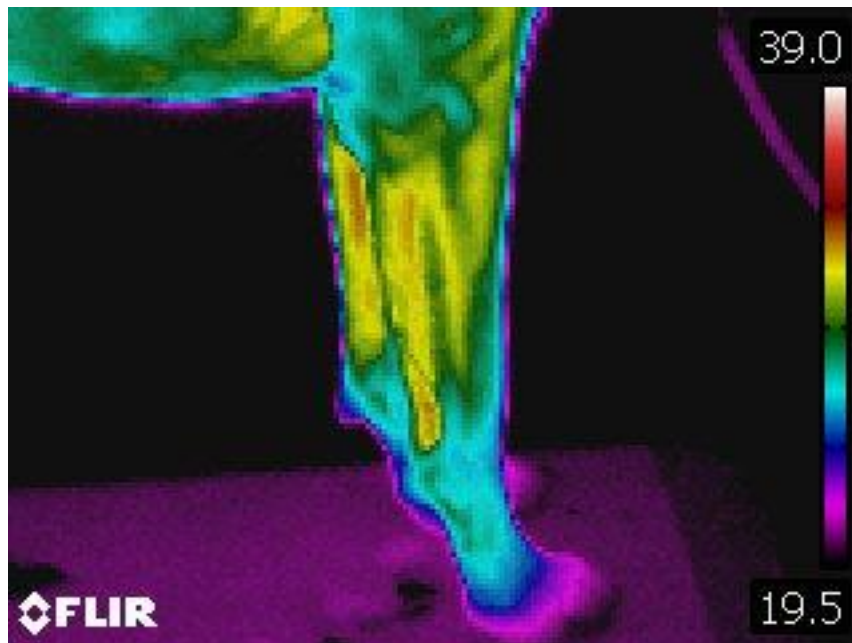
Left Side Profile



Right Side Profile

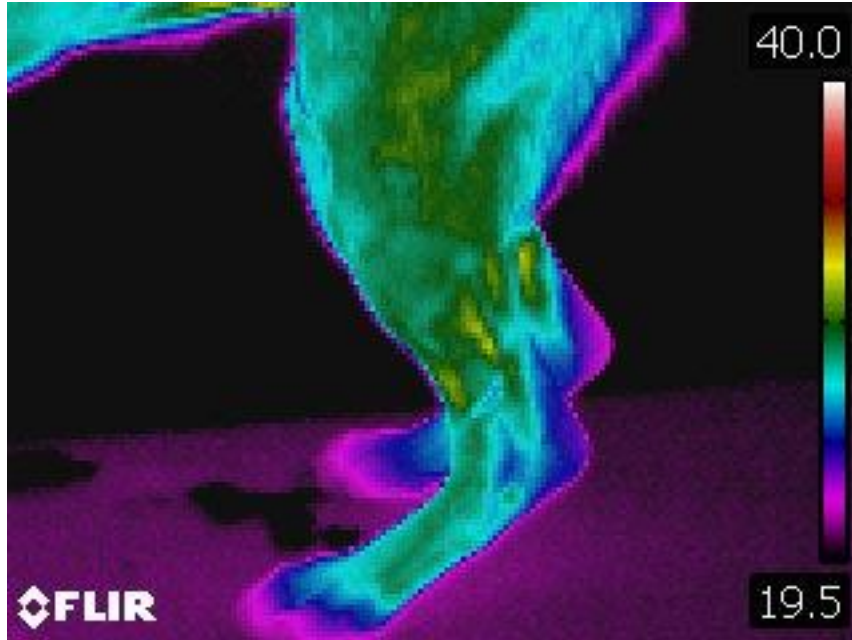


Left Forelimb

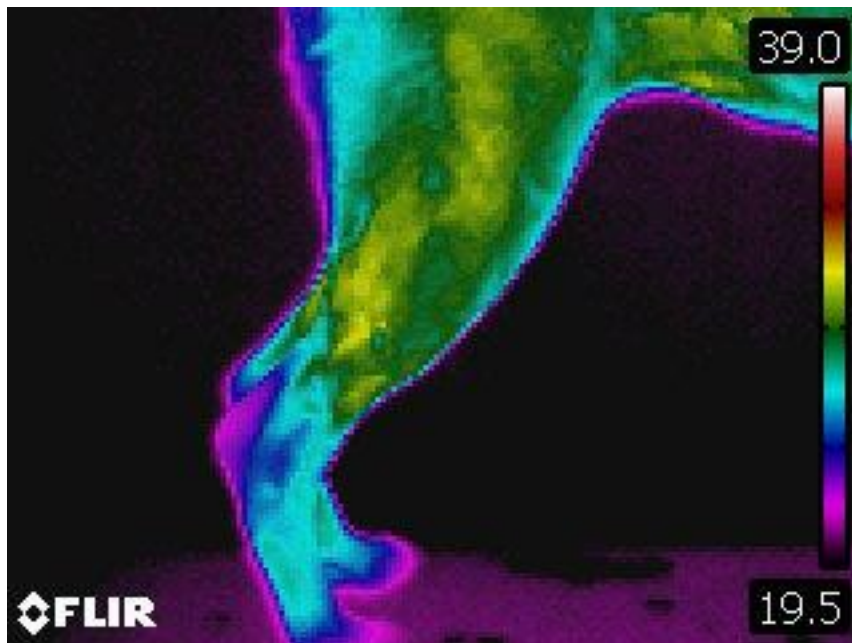


Right Forelimb

There is more heat on the right forelimb from elbow to carpus than on the left. However, the left shoulder demonstrates more heat than the right.

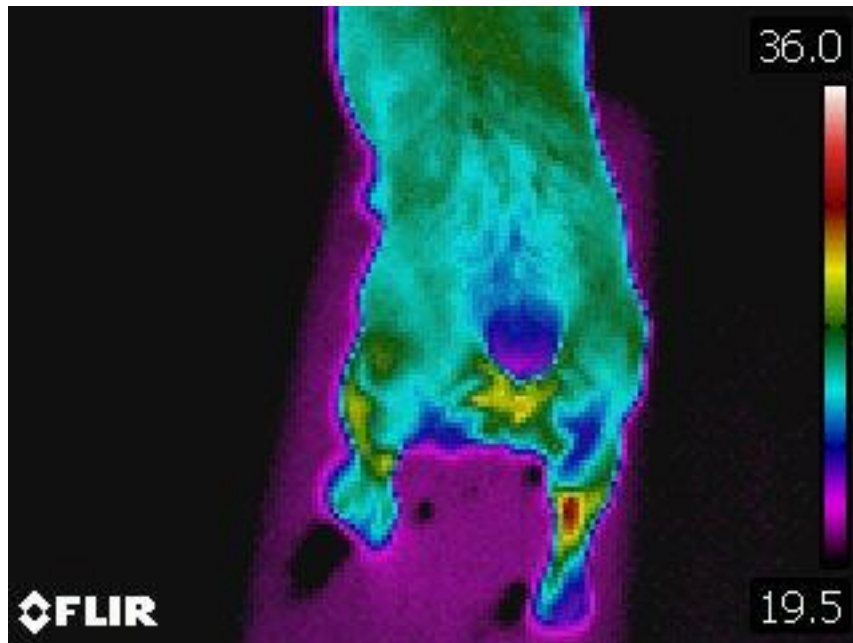


Left rear leg




Right rear leg

The right rear leg is showing slightly more heat than the left in the quadriceps and outer thigh region. However, Doggy's whole right side shows slight more heat than her left in general, and may be the result of the environment or the camera's auto adjustment for ambient temperature between the two sides.

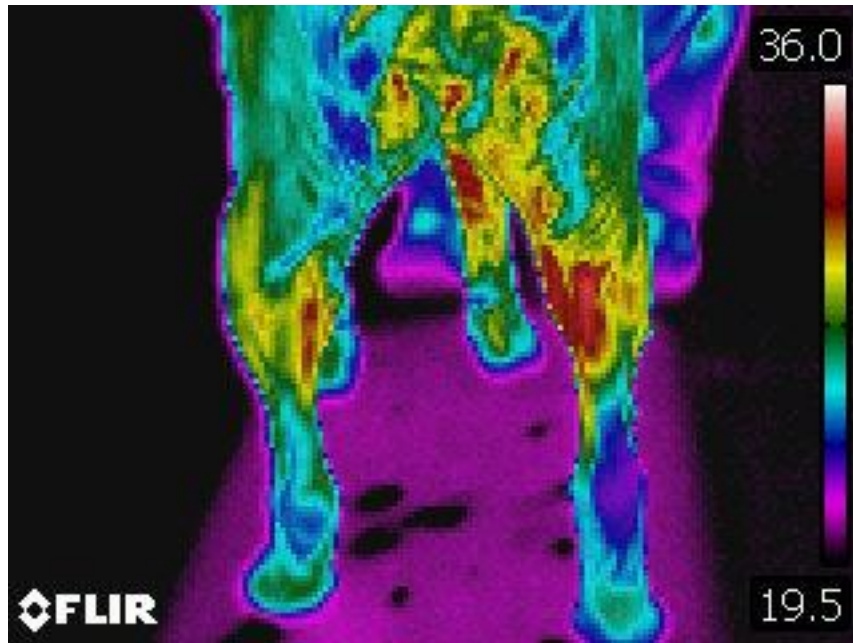


Overhead view back and rear

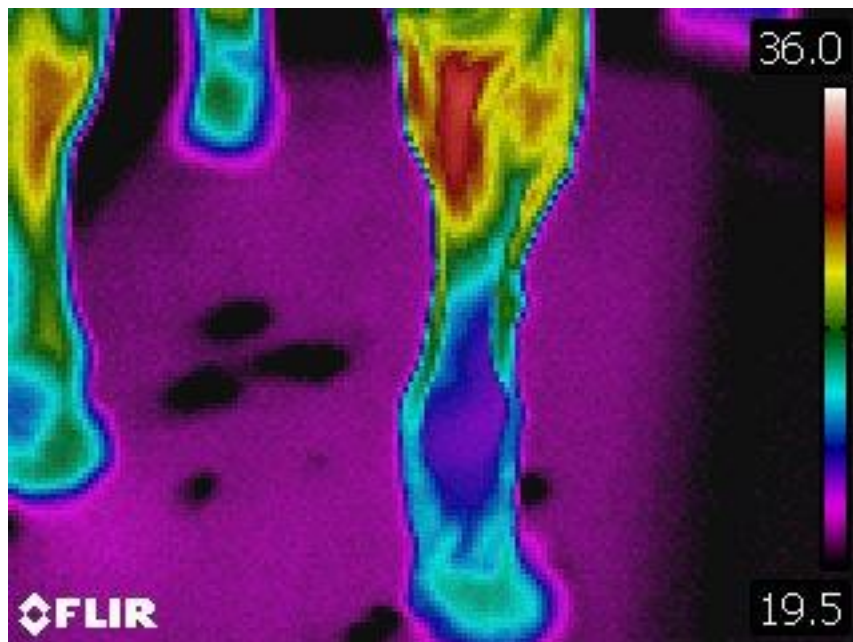


Overhead view head and neck

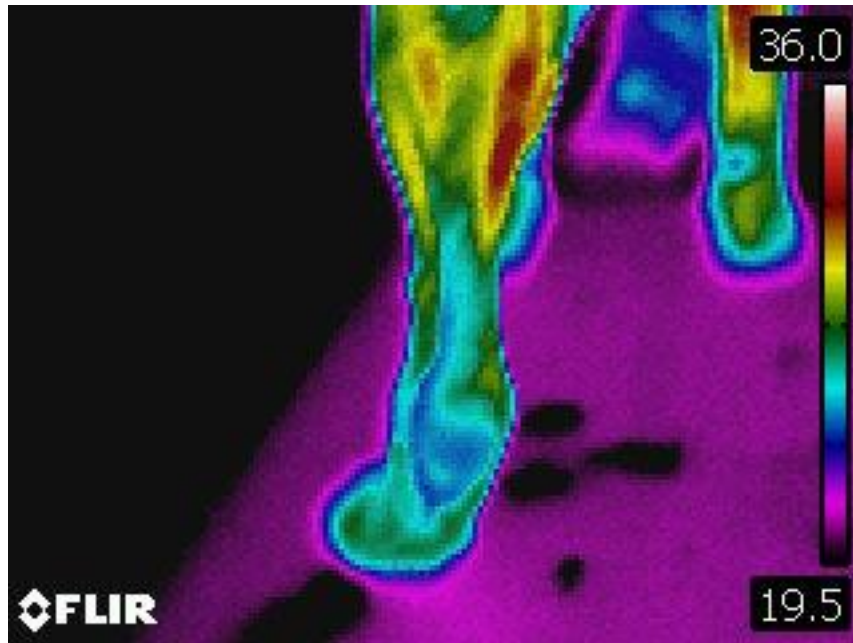
No concerns noted in these two overhead views.



Rear View



Right stifle & hock

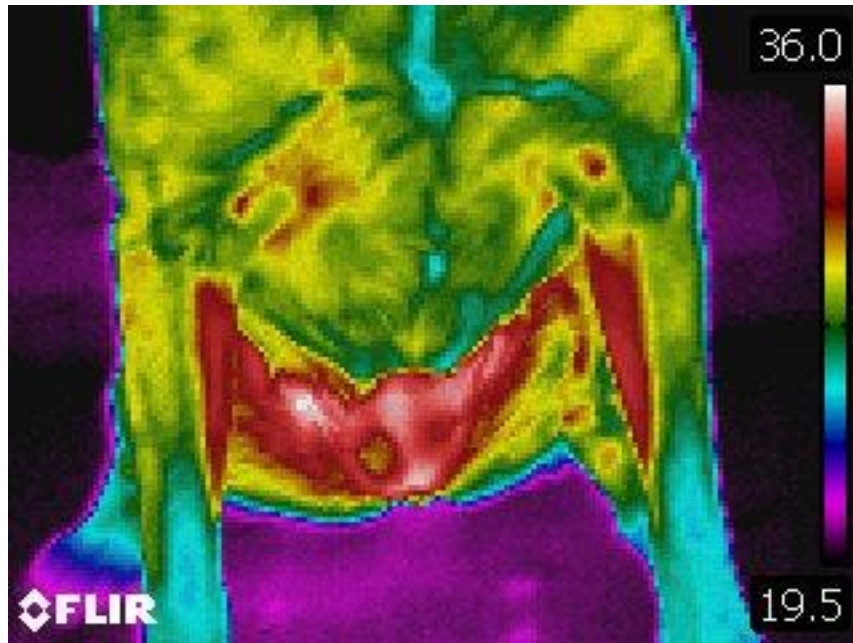


Left stifle & hock

There appears to be more heat in the inner side of the right hind leg; stifle to inner thigh, as compared to the left. The hock however appears much cooler in comparison to the left.

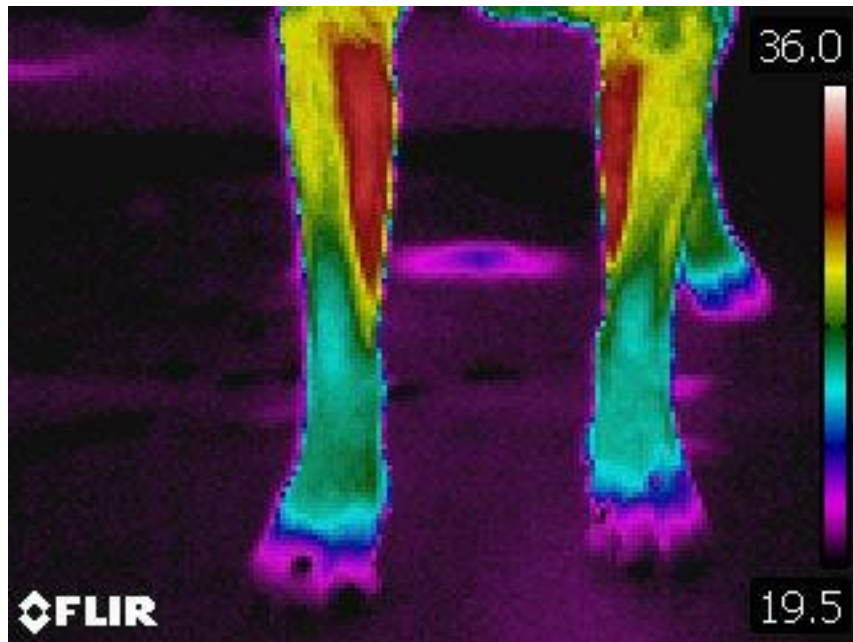


Front & chest



Chest

In these views the right shoulder and pectoral areas show more heat than the left.



Distal forelimbs

The differences in the distal forelimbs is not significant enough to be of concern. The differences seen from side to side in the view above could be due to the stance or weight bearing of the animal. She has a 'cold' toe on the right front leg as well.

Stance Analyzer / Weight Bearing

Left Front: 32% Right Front: 27%

Left Hind: 22% Right Hind: 21%

Comments: 'Normal' would be 30-30 for the Forelimbs and 20-20 for the rear limbs. Doggy McDog may be off loading her right front limb based on this evaluation.

Balance Testing

Doggy McDog did very well with all tests in this station. (40 seconds was our stopping point.)

Her cross-leg standing tests were as follows:

40 seconds for her LH/RF combination & 38 seconds for her RH/LF combo on a flat surface

40 seconds for each diagonal combination on the unstable surface.

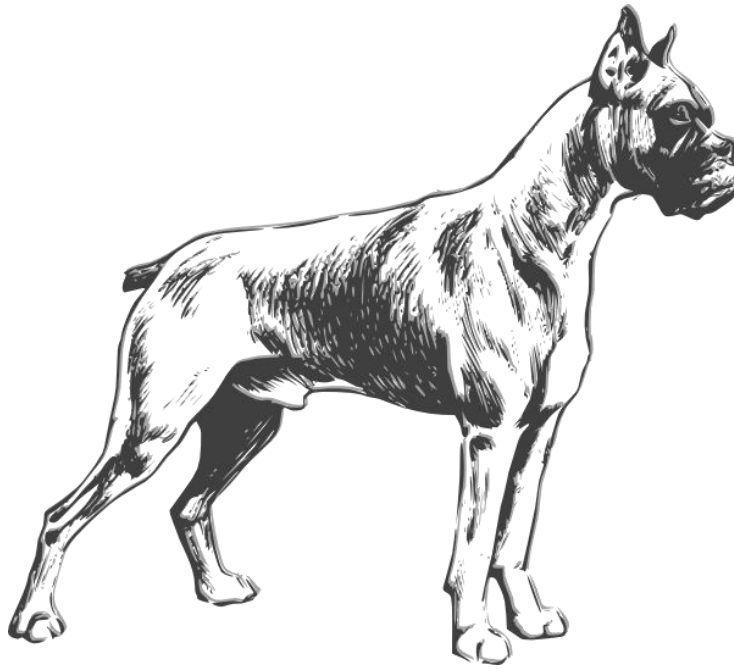
She was also able to complete a 40 second plank (at 12 inches past her normal stance).

Additionally, she had good motor control (no pelvis drop) with the 'Leg Slide Test' with the slide of each individual rear leg

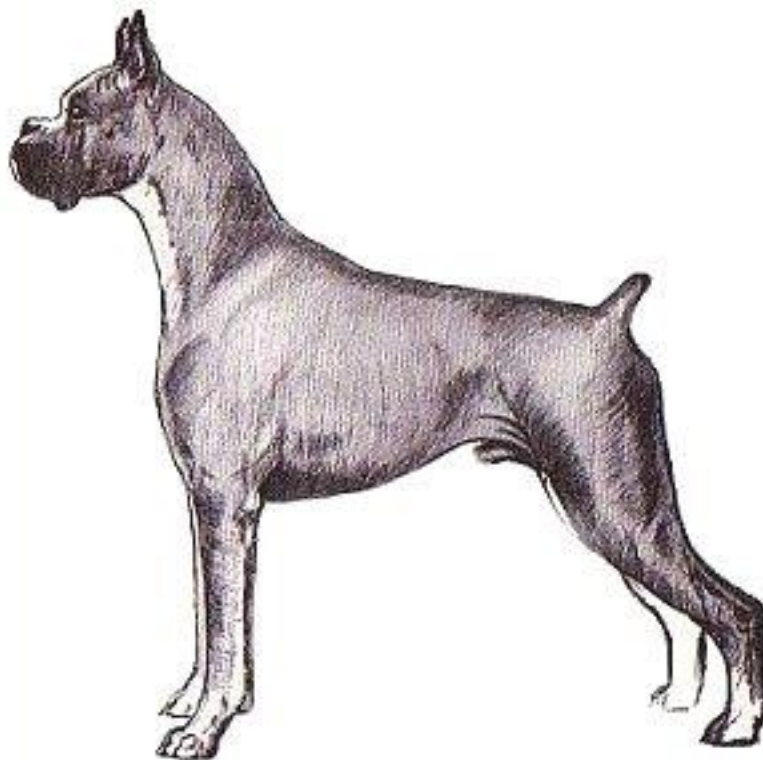
Gait Analysis

Doggy has a mild lameness on her right front leg. However, she warmed out of it in the second video.

Photos



Right Side



Left Side

Extremity Joint Palpation & Testing

RIGHT FORELIMB

The right shoulder displayed guarding with flexion at about 75% range. She was also tender on palpation of her supraspinatus tendon.

Her measured shoulder abduction on this side was 30 degrees (normal).

LEFT FORELIMB

The left shoulder also displayed guarding with flexion, however end range was achieved. Her scapular mobility was also restricted. On palpation, Doggy McDog was tender on her subscapularis tendon (on the innermost side of the joint).

Her measured abduction on this side was 22 degrees. Given the tenderness of her subscapularis, this measurement may actually be a reflection of guarding and protection of the joint.

RIGHT HIND LIMB

Doggy has myofascial trigger points in her Sartorius muscle (front of the thigh) on this side. She also had some tenderness in the back of her stifle. This might indicate a mild degree of arthritis in the joint, since all tests for the cruciate ligament were normal.

LEFT HIND LIMB

Her stifle joint on this side was sore with end range extension and there was also tenderness in the back of the joint. Additionally, it was found that she had a small amount of drawer when testing the cruciate ligament. These findings may indicate that she has had a small strain of her cruciate ligament and there is some subsequent joint irritation.

Additionally, due to a rear foot broken D1 (toe) in February 2018, she was still tender to passive range of motion of this toe – mostly into end range flexion.

Comments: These findings may indicate that Doggy McDog has some degree of medial shoulder hypermobility of her left shoulder, an arthritic right stifle, and a partial strain of her left cruciate ligament.

Spinal Evaluation

Doggy was tender at C7 at the base of her neck.

She was also tender from T6 to T13 and had an increase in adjacent muscle tone between T12 – L2.

In the thorax, she was tender on both Ribs 1 (which may correspond to the C7 tenderness). She was additionally tender on ribs 2 – 7 and rib 10 on the left, and just slightly tender on ribs 2 & 3 on the right. Her intercostal muscle (between the ribs) were tender between ribs 1 – 8 on the left and slightly between ribs 1 & 3 on the right.

She had no tenderness in her lumbar spine.

Her pelvis was asymmetric, with the left ilium appearing more dorsal (rocked backwards) compared to the right. She was tender in the right piriformis muscle as well.

Comments: Doggy McDog may have joint or disc issue at the base of her neck / beginning of her back. Additionally, there were back issues, rib issues, and a sacroiliac joint issue.

Clinical Impression

Overall, Doggy demonstrated some issues in both shoulders and stifles. She had a mild right front leg lameness and also off-loaded this limb on stance evaluation. Additionally, her low neck and a few ribs were tender, as was the transition zone between the thoracic and lumbar spine. She also had a pelvic asymmetry / SIJ dysfunction.

Recommendations

Based on these findings, Doggy McDog would be a good candidate for therapies to address her shoulder tendon issues and stifles. Manual therapies to address the spinal issues would also be advised. We would be happy to help you with these issues should you choose.

Thank you again for bringing Doggy for a Sporting Dog Assessment.

Sincerely,



Laurie Edge-Hughes, BScPT, MAnimSt (Animal Physiotherapy), CAFCI, CCRT