




# CFC News

Spring 2020

## The Intervertebral Disc Disease Issue

Intervertebral disc disease (IVDD) can encompass a number of different types of disc lesions. This newsletter will briefly discuss the types of disc lesions as well as how physical therapy can address the neurological deficits either post-operatively or conservatively with goal directed (and evidence based) treatment strategies. As always, we are here to help serve your patients and be an adjunct to veterinary care. We hope you enjoy this newsletter.



### CANINE REHAB LITERATURE

Bruno E et al. **Perilesional photobiomodulation therapy and physical rehabilitation in post-operative recovery of dogs surgically treated for thoracolumbar disk extrusion.** BMC Vet Res. 2020;16(1):120.

All dogs treated with laser therapy showed improved neurological status (Modified Frankel Score more than 3 within 30 days of physiotherapy starting) if deep nociception on admission was maintained. There was a tendency for a shorter mean time of  $14.2 \pm 8.55$  days in the laser group versus  $24 \pm 18.49$  days in the no laser group for return to ambulation.

- Rehab included soft tissue treatments, passive range of motion, & limb stretching progressing to proprioception and balance exercises, sit to stand exercises, cavaletti rails, and underwater treadmill.
- Laser was applied daily for a minimum of 14 days.

## Intervertebral Disc Disease - Firstly, Identify the Problem:

<p><b>Hansen Type 1 IVDD:</b></p> <ul style="list-style-type: none"> <li>- Chondrodystrophic breeds, 3 – 7 years of age</li> <li>- Cervical or Thoracolumbar localization</li> <li>- Often sudden onset of mild to severe neuro signs</li> <li>- Note: Degenerative changes can be seen in the disc as early as 3 – 4 months of age</li> </ul>	<p><b>Hansen Type 2 IVDD:</b></p> <ul style="list-style-type: none"> <li>- Slow degeneration of the disc characterized by lack of oxygen and blood flow in the disc</li> <li>- Progressive signs of paraparesis, involving back pain and taking weeks, months, or years in development</li> </ul>
<p><b>ANNPE – Acute Non-Compressive Nucleus Pulposus Extrusion</b></p> <ul style="list-style-type: none"> <li>- High velocity extrusion of disc material resulting in bruising to the spinal cord without sustained compression</li> <li>- Any breed (&amp; Border Collies), average age of 7</li> <li>- T3-L3 or cervical spine, often with lateralization</li> <li>- Associated with exercise or trauma, and resulting in a severe, sudden neurologic deficit with vocalization at time of incident</li> <li>- 21 – 57% have spinal pain</li> </ul>	<p><b>HNPE – Hydrated Nucleus Pulposus Extrusion</b></p> <ul style="list-style-type: none"> <li>- Extrusion of hydrated disc material due to sudden changes in disc pressure or biomechanics</li> <li>- Older dogs, average age of 9</li> <li>- Cervical spine more often affected</li> <li>- Spontaneous onset, rarely associated with exercise</li> <li>- Less spinal pain</li> </ul>
<p><b>FCE – Fibrocartilaginous Embolism</b></p> <ul style="list-style-type: none"> <li>- Vascular disease whereby disc material affects spinal blood vessels resulting in ischemic necrosis of dependent regions of the spinal cord</li> <li>- Large or giant breeds (&amp; Miniature Schnauzers) of any age</li> <li>- Lateralization in 53 – 87%</li> <li>- Spinal pain is uncommon</li> </ul>	

### References:

1. De Decker S, Fenn J. Acute Herniation of Nondegenerate Nucleus Pulposus: Acute Noncompressive Nucleus Pulposus Extrusion and Compressive Hydrated Nucleus Pulposus Extrusion. *Vet Clin North Am Small Anim Pract.* 2018, Jan;48(1):95-109.
2. De Risio L. A review of fibrocartilaginous embolic myelopathy and different types of peracute non-compressive intervertebral disk extrusions in dogs and cats. *Frontiers Vet Sci.* 2015, 2:24.
3. Hansen T, Smolders L, Tryfonidou M et al. The myth of fibroid degeneration in the canine intervertebral disc: A histopathological comparison of intervertebral disc degeneration in chondrodystrophic and nonchondrodystrophic dogs. *Vet Pathology.* 2017, 54(6): 945-952.
4. Risbud M & Shapiro I. Notochordal cells in the adult intervertebral disc: new perspective on an old question. *Crit Rev Eukaryot Gene Expr.* 2011, 21(1): 29-41.
5. Smolders L, Bergknut N, Grinwis GC et al. Intervertebral disc degeneration in the dog. Part 2: chondrodystrophic and non-chondrodystrophic breeds. *Vet J.* 2013, 195(3): 292-299.

It is generally accepted that surgery is the best choice for a severely compromised Hansen Type 1 Disc lesion. The rest are in need of comprehensive conservative management. Additionally, should the chondrodystrophic Type 1 patient not be a good surgical candidate (for whatever reason – health, age, finances, or owner willingness), then conservative management can be offered. As well, other than the addition of incision care, rehab for a post-operative disc lesion will follow the same basic goals and treatment strategies as conservative management.

## INTERVERTEBRAL DISC DISEASE MANAGEMENT HINGES ON THE FOLLOWING

- ▶ Should be GOAL oriented
- ▶ Should address the underlying pathology
- ▶ Should address function
- ▶ Should include routine re-evaluation of the neurologic status of the animal by the therapy provider.

### GOAL: PAIN RELIEF

Spinal hyperaesthesia is a common clinical finding in the majority of dogs with thoracolumbar IVDD. Physiotherapy modalities such as laser, ultrasound, transcutaneous electrical neuromuscular stimulation, pulsed electromagnetic field therapy, microcurrent, or heat and ice, have been shown to have pain-relieving effects. These tools can be utilized frequently in the initial stages to improve comfort and act as an adjunct to medical management. Acupuncture has also been shown to diminish pain. Western medicine has been able to demonstrate how the application of needles to the body can target different aspects of the nervous system, endocrine system, and vascular system to result in pain relief.

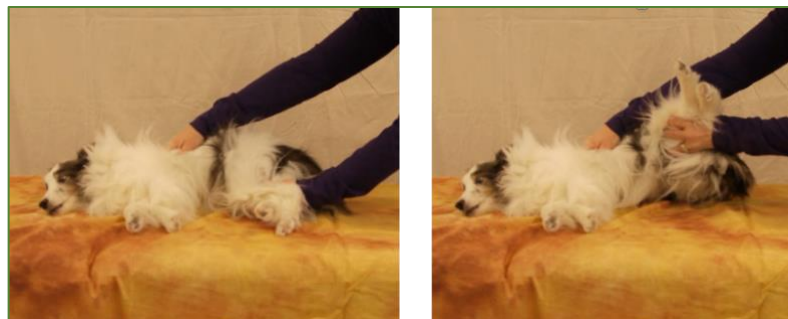

### GOAL: ADDRESS THE DISC EXTRUSION, CORD INFLAMMATION, AND SPINAL CORD REPAIR

In humans, it has been found that exposure of herniated disc material in the cervical spine to the vascular environment of the epidural space contributes to its resorption and/or regression. Large extruded discs have wider exposure to resorption mechanisms and tend to regress more rapidly. In fact, the response to early therapeutic intervention in cases where there is a large extruded disc is most favourable. A technique for dachshunds could be 'hanging traction', whereby the owner slowly and gently picks up the dog so that the animal's spine is against the owner's chest. The owner hugs the animal and allows its hind end to hang and dangle which may traction the spine. This treatment should cease if the animal struggles or symptoms worsen.



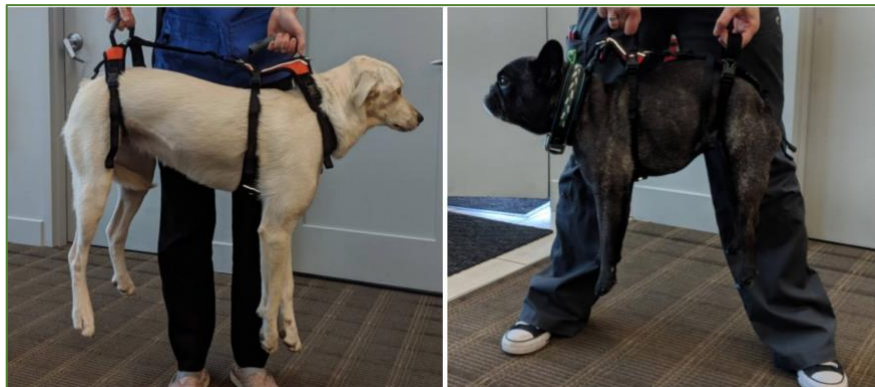Utilizing human and animal research, mobilizations have been shown to aid in pain relief for spinal or joint conditions. Mobilization technique selection for disc lesions in people tends to incorporate rotational components. Simply lying a dog on its side and slowly lifting both rear legs at a time so as to create a rotational motion in the spine can provide both pain relief and enhanced blood flow.



The modalities discussed for pain management may also play a role in directly or indirectly aiding in blood flow to the region, which could help with disc resorption but may also reduce edema and inflammation around the spinal cord. Both pulsed electromagnetic field and laser therapy (class 3b) have been studied in animal models of spinal cord injury, and were shown to improve axonal sprouting, spinal cord repair, and motor function. A study that looked at electroacupuncture for dogs with IVDD with severe neurologic deficits (grade 4 or 5) of greater than 48-hours duration as compared to decompressive surgery found that the electroacupuncture was significantly more effective than surgery for recovery of ambulation. Newer studies even show that intravenous transplantation of stem cells (bone marrow derived or adipose derived) is effective for reduced inflammation and improvement in motor function in spinal cord injured rats and dogs.

### **GOAL: LIFESTYLE MANAGEMENT**

Perhaps equally as important as what the practitioner should do, is the advisement of what the animal and owners should not do! To avoid re-injury, owners should be advised to restrict the dog to no playing, no running off leash, no jumping and no self-ambulating down stairs during the acute and intermediate stages of healing. The first two restrictions will protect against sudden twisting motions, and the latter two will inhibit forced flexion forces on the spine and discs. Flooring can make a difference too! Animals may ambulate with greater ease, confidence, and success if non-slip footing (i.e. rubber-backed throw rugs) is provided for slippery floors or other types of modifications such as booties, ToeGrips™, or a harness. Owners should also be advised of the seriousness of the condition and the potential to progress to a more severe lesion if proper management is not undertaken in this stage.

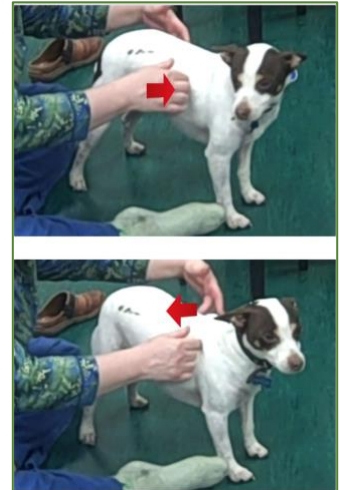


### **GOAL: GROSS MOTOR STRENGTHENING AND CO-ORDINATION TRAINING**

Gentle, non-harmful, easy exercise is imperative to healing and re-establishment of neural pathways. Controlled exercise has shown to be a clearly effective treatment for chronic low back pain in people. Human disc patients are no longer prescribed bed rest, they are now told to walk. Therefore, once the animal is no longer painful or minimally painful and has safe motor functioning, then a leash-walking program should commence. Leash walks should start with distances and times that are within the dog's tolerance. Swimming with a floatation vest or water walking may also accomplish this goal. A weak animal may be able to successfully walk in water due to the buoyancy of the water.



Stabilizing exercises should target the abdominals. Abdominal muscles function in maintaining static postures and can be further facilitated by rhythmic stabilization techniques. Rhythmic stabilization is accomplished by gently pushing the patient one way, then the other way, alternating pressures rhythmically in order to enhance muscular recruitment of core stabilizing muscles. This can be done with the dog in sternal recumbency, sitting, or standing. When able more challenging balancing exercises can be prescribed (such as balancing while standing or sitting on an exercise ball or similar piece of equipment). Progressions to this exercise can be done by lifting one leg at a time while the dog balances or having the animal take a treat from different directions, or imparting a manual perturbation. Owners should not be given these exercises unless taught how to do them safely by a person trained in canine rehabilitation.



As the dog progresses, the practitioner will need to address coordination problems with movement. The ataxic animal will require neuromotor re-programming. When safe to do so, animals can begin co-ordination retraining to help build balance and proprioceptive function. Tasks such as walking through weave poles, over obstacles, balancing on a raised plank of wood, backing up, and sideways walking may be incorporated into an exercise regimen to stimulate coordination training when in the dog is no longer acute and has progressed into a recovery stage. Generalized strengthening can be taken into account as well. Walking up and down hills or stairs or engaging in safe tug-of-war play may help to strengthen deconditioned limb muscles.

## CONCLUSION

Conservative management of thoracolumbar disc disease is a viable option and should be added to a veterinarian's list of management options being presented to an owner. Post-operative rehab should be considered standard of care for the neurologic patient. Practitioners trained in rehabilitation and acupuncture can serve as a resource and referral destination for owners seeking post-operative or non-surgical interventions.

## CANINE REHAB LITERATURE

Jeong IS et al. **Canine thoracolumbar intervertebral disk herniation and rehabilitation therapy after surgical decompression: A retrospective study.** *J Adv Vet Anim Res.* 2019;6(3):394-402.

Rehabilitation therapy after surgical decompression of thoracolumbar IVDH improves neurologic functions and increases the success rate, especially when the preoperative pathological condition is severe.

- 86.46% (83/96) of dogs had a successful neurologic outcome in the Rehab Group, which was significantly ( $p < 0.01$ ) higher than the Non-Rehab Group 52.22% (47/90).

## **FOCUS on Fibrocartilaginous Embolism – A REWARDING CONDITION FOR REHAB**

Fibrocartilaginous embolic myelopathy (FCEM) is a common and very rewarding condition to treat in the canine rehabilitation clinic.

Fibrocartilaginous embolic myelopathy is a vascular disease of the spinal cord caused by embolization of spinal vasculature with fibrocartilaginous material histologically and histochemically identical to the nucleus pulposus of the intervertebral disk, resulting in ischemic necrosis of dependent regions of spinal cord. Various theories have been hypothesized to explain how the fibrocartilaginous material can enter the spinal vasculature. FCEM is considered as the most common cause of ischemic myelopathy in dogs. There is no clinical test currently available to absolutely confirm a diagnosis of a fibrocartilaginous embolism (FCE). Initially the aim is to differentiate between FCEM and other conditions such as intervertebral disc disease, a fracture, or a spinal tumor -- all of which can cause considerable pain. If the dog is not in pain, that is one factor that can be indicative of an FCE. The best imaging technique for a fibrocartilaginous embolism is the MRI, because it can distinguish between an obstruction (i.e. an embolism) and a compression or swelling of the spinal cord.

Neurologic signs are peracute in onset and the severity and distribution of the signs are directly in relation to the site and the extent of spinal cord infarction. The neurologic signs usually stabilize in the initial 24 hours and then may remain static or improve depending on the severity and the extent of the ischemia and speed in which rehabilitation is instituted. FCEM is considered as the most common cause of ischemic myelopathy in dogs. The general thought is that the severity of neurological signs at the time of initial examination and MRI (if used), are associated with the outcome. The variable in this outcome however was seen when physiotherapy including hydrotherapy was instituted immediately after the diagnostic work-up. These cases saw a major improvement in recovery rate and overall function. Another study reported no additional benefit when comparing dogs treated with physiotherapy alone versus those treated with physiotherapy and corticosteroids.

FCE development has been reported predominantly at the vertebral levels C6-T2 and L4-S3. It is noted that there is a positive correlation between a poor prognosis and the involvement of intumescences, symmetrical clinical signs and decreased deep pain sensation. However, physiotherapy and/or hydrotherapy instituted immediately after the diagnosis seems to have a major influence on the recovery. One study indicated that early precise diagnosis as well as early onset of treatment are important to obtain a favorable prognosis. This study noted treatment commenced in less than 15 days. In dogs with FCEM, time intervals between onset of neurological signs and recovery of voluntary motor activity, unassisted ambulation, and maximal recovery have been reported as varying between 6 days and 3.75 months.

One study reported that 88% of the dogs were small to medium sized which is not the usual demographic that is reported. Most commonly this condition has been reported in large and giant breed non-chondrodystrophic dogs. However, it has also been described frequently in small breed dogs (particularly miniature schnauzers). The male to female ratio in dogs ranges from 1:1 to 2.5:1 in different studies. The age at diagnosis is an average of 4-6 years old. Onset of neurological dysfunction during physical activity, such as running, jumping, or playing, is common but occasionally no triggering event is noted. Marked lateralization of neurological dysfunction has been reported as 53–87% in various studies on FCEM.

## Treatment

Treatment will vary with each case and will depend on a thorough evaluation when the dog presents for rehabilitation. We have seen dogs as early as 24-hours post onset. Treatment can range from initial passive range of motion, bed positioning and instruction to manage activities of daily living (ADL) for the owners such as lifting aides like the 'Help Em Up' harness, addressing bowel and bladder routines, and prevention of pressure sores. A wide range of modalities can be used for these dogs from laser, pulsed magnetic field, microcurrent, acupuncture and electrical muscle stimulation, all depending on the findings at evaluation. There will also be very specific therapeutic exercises which will be tailored to each case and will be ever changing throughout the progression of recovery. Both pool and underwater treadmill can be extremely useful at varying times during the course of recovery as well.

Because these dogs usually have an excellent prognosis the owners are eager to become involved in their home exercise programs and to help their pet reach maximum functional recovery. A fun and rewarding case for all involved.

## References:

1. De Riso L & Platt SM. Fibrocartilaginous Embolic Myelopathy in Small Animals. *Vet Clin Small Anim* 40 (2010) 859–869.
2. De Riso L, Adams V, Dennis R, et al. Association of clinical and magnetic resonance imaging findings with outcome in dogs suspected to have ischemic myelopathy: 50 cases (2000–2006). *J Am Vet Med Assoc.* July 1, 2008, Vol. 233, No. 1, Pages 129-135.
3. Nakamoto Y, Ozawa T, Katakabe K, et al. Fibrocartilaginous Embolism of the Spinal Cord Diagnosed by Characteristic Clinical Findings and Magnetic Resonance Imaging in 26 Dogs *Journal of Veterinary Medical Science* 2009.
4. Nakamoto Y, Ozawa T, Katakbe K, et al. Usefulness of an early diagnosis for the favorable prognosis of fibrocartilaginous embolism diagnosed by magnetic resonance imaging in 10 Small- to Middle-Sized Dogs. *Veterinary Research Communications* May 20, 200.
5. De Riso L. A review of fibrocartilaginous embolic myelopathy and different types of peracute non-compressive intervertebral disk extrusions in dogs and cats  
Luisa De Riso. *Front. Vet. Sci.*, 18 August 2015.
6. Gandini G, Cizinauskas S, Lang J, et al. Fibrocartilaginous embolism in 75 dogs: clinical findings and factors influencing the recovery rate. *J Small Anim Pract.* 2003 Feb;44(2):76-80.

---

**The Canine Fitness Centre Ltd.** is also available for wheelchair fitting, rental, or measuring for the purpose of ordering.



